

Circulation

JOURNAL OF THE AMERICAN HEART ASSOCIATION



Prevention of Ventricular Fibrillation Episodes in Brugada Syndrome by Catheter Ablation Over the Anterior Right Ventricular Outflow Tract Epicardium

Koonlawee Nademanee, Gumpanart Veerakul, Pakorn Chandanamattha, Lertlak Chaothawee, Aekarach Ariyachaipanich, Kriengkrai Jirasirojanakorn, Khanchit Likittanasombat, Kiertijai Bhuripanyo and Tachapong Ngarmukos

Circulation published online Mar 14, 2011;

DOI: 10.1161/CIRCULATIONAHA.110.972612

Circulation is published by the American Heart Association, 7272 Greenville Avenue, Dallas, TX 75214

Copyright © 2011 American Heart Association. All rights reserved. Print ISSN: 0009-7322. Online ISSN: 1524-4539

The online version of this article, along with updated information and services, is located on the World Wide Web at:

<http://circ.ahajournals.org>

Data Supplement (unedited) at:

<http://circ.ahajournals.org/cgi/content/full/CIRCULATIONAHA.110.972612/DC1>

Subscriptions: Information about subscribing to Circulation is online at
<http://circ.ahajournals.org/subscriptions/>

Permissions: Permissions & Rights Desk, Lippincott Williams & Wilkins, a division of Wolters Kluwer Health, 351 West Camden Street, Baltimore, MD 21202-2436. Phone: 410-528-4050. Fax: 410-528-8550. E-mail:
journalpermissions@lww.com

Reprints: Information about reprints can be found online at
<http://www.lww.com/reprints>

Prevention of Ventricular Fibrillation Episodes in Brugada Syndrome by Catheter Ablation Over the Anterior Right Ventricular Outflow Tract Epicardium

Koonlawee Nademanee, MD; Gumpanart Veerakul, MD; Pakorn Chandanamatttha, MD; Lertlak Chaothawee, MD; Aekarach Ariyachaipanich, MD; Kriengkrai Jirasirojanakorn, MD; Khanchit Likittanasombat, MD; Kiertijai Bhuripanyo, MD; Tachapong Ngarmukos, MD

Background—The underlying electrophysiological mechanism that causes an abnormal ECG pattern and ventricular tachycardia/ventricular fibrillation (VT/VF) in patients with the Brugada syndrome (BrS) remains unelucidated. However, several studies have indicated that the right ventricular outflow tract (RVOT) is likely to be the site of electrophysiological substrate. We hypothesized that in patients with BrS who have frequent recurrent VF episodes, the substrate site is the RVOT, either over the epicardium or endocardium; abnormal electrograms would be identified at this location, which would serve as the target site for catheter ablation.

Methods and Results—We studied 9 symptomatic patients with the BrS (all men; median age 38 years) who had recurrent VF episodes (median 4 episodes) per month, necessitating implantable cardioverter defibrillator discharge. Electroanatomic mapping of the right ventricle, both endocardially and epicardially, and epicardial mapping of the left ventricle were performed in all patients during sinus rhythm. All patients had typical type 1 Brugada ECG pattern and inducible VT/VF; they were found to have unique abnormal low voltage (0.94 ± 0.79 mV), prolonged duration (132 ± 48 ms), and fractionated late potentials (96 ± 47 ms beyond QRS complex) clustering exclusively in the anterior aspect of the RVOT epicardium. Ablation at these sites rendered VT/VF noninducible (7 of 9 patients [78%]; 95% confidence interval, 0.40 to 0.97, $P=0.015$) and normalization of the Brugada ECG pattern in 89% (95% confidence interval, 0.52 to 0.99; $P=0.008$). Long-term outcomes (20 ± 6 months) were excellent, with no recurrent VT/VF in all patients off medication (except 1 patient on amiodarone).

Conclusions—The underlying electrophysiological mechanism in patients with BrS is delayed depolarization over the anterior aspect of the RVOT epicardium. Catheter ablation over this abnormal area results in normalization of the Brugada ECG pattern and prevents VT/VF, both during electrophysiological studies as well as spontaneous recurrent VT/VF episodes in patients with BrS. (*Circulation*. 2011;123:1270-1279.)

Key Words: Brugada syndrome ■ catheter ablation ■ arrhythmia ■ electrophysiology ■ mapping

Since it was first recognized in 1992, the Brugada syndrome (BrS) has drawn worldwide attention as an important clinical entity that causes premature death in young adults who are otherwise apparently healthy.¹ The syndrome is an autosomal inherited disease with variable transmission and is characterized by ST-segment elevation in the right precordial ECG leads; BrS is associated with a high incidence of sudden death because of ventricular fibrillation (VF) in patients with apparently structurally normal hearts. In Thailand, the syndrome is also known as sudden unexplained death syndrome, which was found to have the same phenotype and genotype characteristics as BrS.^{2,3}

Clinical Perspective on p 1279

Currently, an implantable cardioverter defibrillator (ICD) is the only proven effective treatment for symptomatic patients, especially for those who have experienced aborted sudden cardiac death.⁴ However, ICD implantation may not be an adequate solution for many patients (eg, infants and young children or patients residing in regions of the world where an ICD is unaffordable). Furthermore, some of the symptomatic patients with BrS who receive ICD implantation often experience frequent ICD shocks,⁴ which pose a therapeutic challenge for physicians. Although quinidine has been

Received June 16, 2010; accepted January 25, 2011.

From the Pacific Rim Electrophysiology Research Institute, Los Angeles, CA (K.N., A.A.); and the Bhumipol Adulyadej Royal Thai Air Force Hospital (G.V., K.J.), Bangkok Heart Hospital (L.C., K.B.), and Ramathibodi University Hospital (P.C., K.L., T.N.), Bangkok, Thailand.

Presented in part at the American Heart Association Scientific Sessions 2010, Chicago IL, November 16, 2010, and published in Abstract form.

The online-only Data Supplement is available with this article at <http://circ.ahajournals.org/cgi/content/full/CIRCULATIONAHA.110.972612/DC1>.

Correspondence to: Koonlawee Nademanee, MD, Pacific Rim Electrophysiology Research Institute, 1700 Cesar E. Chavez Ave, Ste 2700, Los Angeles, CA 90033. E-mail wee@pacificrimpe.com

© 2011 American Heart Association, Inc.

Circulation is available at <http://circ.ahajournals.org>

DOI: 10.1161/CIRCULATIONAHA.110.972612

reported to be effective in treating patients with BrS, the drug is not easy for younger patients to tolerate over a lifetime because of its side effects.⁵

Although an abundance of research has been conducted worldwide, the pathophysiology of the BrS is not well explained. Still unknown is the exact mechanism of the syndrome's signature, right precordial lead ST-elevation, and the exact location of the arrhythmogenic substrates of the life-threatening ventricular arrhythmias, ventricular tachycardia (VT)/VF, in patients with BrS/sudden unexplained death syndrome. Existing data point to the right ventricular outflow tract (RVOT) as the origin for VT/VF in patients with BrS.⁶⁻⁹

A report by Haïssaguerre and coworkers showed that focal radiofrequency ablation of premature ventricular contractions (PVCs), which trigger VT/VF at the RVOT, is effective in preventing VT/VF.⁷ Unfortunately, patients with BrS rarely have frequent PVCs to be mapped. In addition, our data showed that BrS/sudden unexplained death syndrome patients in Thailand rarely had PVCs during Holter monitoring (<1 beat per hour), and when PVCs occurred, they were at night and immediately initiated VF.¹⁰

We hypothesized that identification of the arrhythmogenic substrate in BrS patients would enable ablation as a potential treatment option in patients with recurrent ventricular arrhythmias. On the basis of previous research, we believe that the RVOT is the likely origin for ventricular arrhythmias of BrS patients. Hence, we carried out the following study in the BrS patients who had been suffering from frequent ICD discharges due to VF episodes, aiming to map the RVOT in detail (both at the epicardial and endocardial sites), with the postulate that these sites are likely the arrhythmogenic substrate areas of these patients.

Methods

Study Patients

We prospectively enrolled patients with BrS who had a previous history of out-of-hospital cardiac arrests and ICD implantation. All patients were required to have type 1 Brugada pattern,¹¹ which occurred either spontaneously or after ajmaline infusion, as well as ICD implantation, with multiple shocks that failed to respond to amiodarone (quinidine is not available in Thailand). We excluded patients who had the following conditions: (1) VT/VF caused by identifiable precipitating factors (eg, myocardial ischemia, fever, and hypokalemia); (2) presence of structural heart disease; and (3) brain anoxic encephalopathy from cardiac arrests due to VT/VF. All patients underwent cardiac testing including echocardiogram, computed tomography (CT)/magnetic resonance imaging, and cardiac catheterization to exclude structural heart disease. All patients signed an informed consent that had been approved by our institutional review board.

Electrophysiological Studies and Mapping of the VF Substrate

All patients underwent electrophysiological studies and programmed stimulation for VT induction (3 cycle lengths [600, 500, and 400 ms] up to triple stimuli). Detailed epicardial and endocardial mapping of arrhythmogenic substrate of the RV, as well as epicardial mapping of the left ventricle (LV) was performed during sinus rhythm with a 3.5-mm-tip NaviStar-ThermoCool catheter (Biosense Webster Inc, Diamond Bar, CA). Electroanatomic mapping of the RV and LV was performed during normal sinus rhythm in conjunction with CT image integration (CT was performed within 24 hours of the electrophys-

iological procedure). To gain access into the pericardial space for epicardial mapping, the pericardium was entered using the technique described by Sosa and his coworkers.¹² Femoral arterial pressure was continuously monitored.

First, epicardial and endocardial electroanatomical mapping was performed using the double annotation software on the CARTO XP EP Navigation System (Biosense Webster Inc.), which enabled the creation of maps based on different parameters. The map (A2-A1) is colored according to the duration of local potentials, with the purple and blue areas indicating electrograms of long duration and red areas indicating electrograms of shorter duration. We used the CARTO software that enables the same map to be shown in the voltage map fashion and displayed areas of fractionated signals during sinus rhythm. The voltage of the signal was measured automatically by the software and could be rechecked manually.

Figure 1 shows a map from patient 6 (see also Table 1). It displays the composite picture of an A2-A1 map (to display the duration of the abnormal electrograms) and a sample tracing of the electrograms recorded from the anterior aspect of the RVOT epicardium. The electroanatomic map of the RV epicardium is merged into the cardiac CT.

Once these maps were created and the VF/VT substrate was identified by using late fractionated ventricular potentials as a surrogate for the VF substrate, programmed electric stimulation for VT induction (S1 and S1 at 600, 500, and 400 ms up to triple ventricular stimuli) was performed via the quadripolar catheter in the RV apex or RVOT. After the VT/VF became sustained and unstable and was hemodynamically compromising, cardioversion/defibrillation was performed to restore sinus rhythm.

Definition and Measurement of Abnormal Electrograms and Catheter Ablation

Abnormal electrograms are defined as electrograms that have (1) low voltage (≤ 1 mV); (2) split electrograms or fractionated electrograms with multiple potentials with ≥ 2 distinct components, with >20 ms isoelectric segments between peaks of individual components; and (3) wide duration (>80 ms) or late potentials (LPs), with distinct potentials extending beyond the end of the QRS complex. The interval from the end of the QRS complex to the end of the local electrogram was measured to determine the magnitude of LPs. For the purpose of analysis of the distribution of abnormal electrograms, we divided the mapping into 4 areas: (1) RV epicardium outside of the anterior RVOT, (2) anterior RVOT epicardium, (3) LV epicardium, and (4) RV endocardium.

Figure 2 shows examples of the above-described electrograms, which are critical as target sites for catheter ablation; these sites should also exhibit fast fractionated potential during VF. Radiofrequency ablations were performed at power from 30 to 50 W, with the maximum temperature set at 45°C. The immediate end point during ablation is the elimination of the arrhythmogenic fractionated electrograms yielding either noninducible sustained VT/VF (<10 seconds) or disappearance of the Brugada ECG pattern.

Clinical End Points and Statistical Analysis

All patients were followed at 1 month after the ablation session and every 3 months thereafter. The long-term end points were death and VF episode(s), as detected by ICD interrogation. Exact McNemar test was used to analyze the proportion differences of VF episodes before and after ablation (both spontaneously occurring and induced by programmed stimulation). To compare the number of episodes before and after ablation, Wilcoxon signed-rank test was used. Two-way ANOVA was used to compare the differences of the electrogram voltage, LP, and duration among 4 areas of the epicardial and endocardial sites, treating each patient as a blocking factor. When the interaction was significant, post-ANOVA stratified analyses of the fitted means were conducted. All data were analyzed with a statistical package, SAS version 9.2.

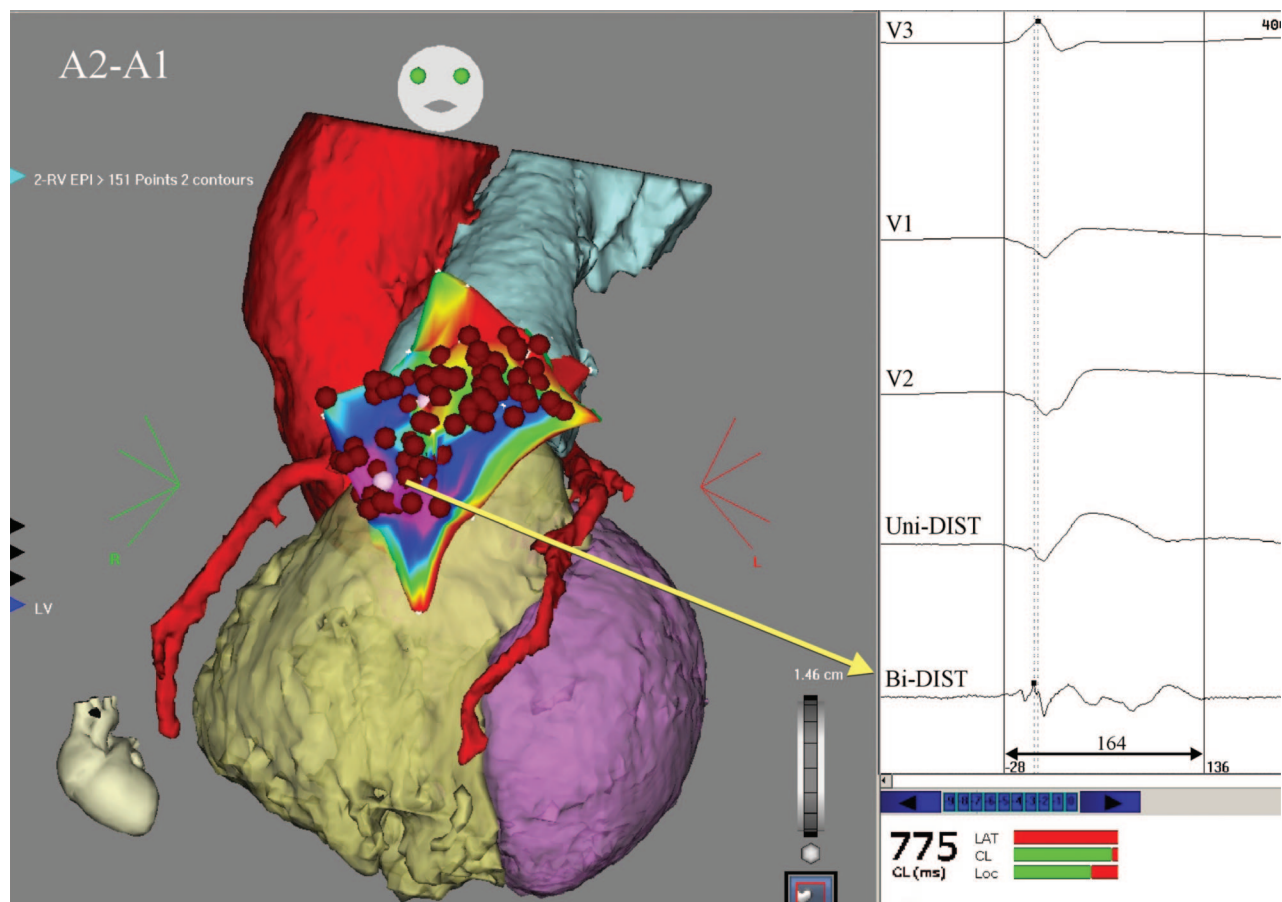


Figure 1. A composite picture of the CARTO-merge maps (patient 6) shows the cardiac computed tomography (CT) of the right ventricle (RV), left ventricle (LV), aorta, pulmonary artery, and coronary arteries that are merged with the electroanatomic maps of the right ventricular outflow tract (RVOT) epicardium (EPI). The double annotation map displays a magnitude of prolonged electrogram duration; the purple area indicates the very prolonged duration of the electrogram (>150 ms). The sample electrograms recorded from this area are shown (right). The bipolar electrogram recorded from the distal pair-electrodes of the NaviStar-ThermoCool catheter at the purple area of the map is low voltage (0.43 mV) and fractionated with the electrogram width of 164 ms. The unipolar electrogram recorded from the distal electrode is also shown, along with the right precordial leads (V1 through V3). The red dots represent ablation points; Bi-DIST, bipolar distal; Uni-DIST, unipolar distal; LAT, local activation time; CL, cycle length; Loc, location; R, right; and L, left.

Results

Thirteen male BrS patients with frequent ICD discharges were evaluated. We excluded 4 patients from the study; 2 patients were excluded because VT/VF subsided after correction of

hypokalemia, and 2 had brain anoxic encephalopathy. The remaining 9 patients who underwent the study had a median age of 38 years (range 24 to 53 years) and recently suffered from frequent ICD discharges due to VF episodes (median 4 episodes)

Table 1. Clinical Characteristics of the Study Patients

Patient	Age	Sex	BrS-ECG	VF Episodes per Month, n	Initial Symptoms	BrS ECG After, Yes/No	Inducible Before	Inducible After	Time from ICD to First Episodes, mo	Follow-Up Period, mo
1	29	M	Yes	5	CA	Yes	Single	Noninducible	4	33
2	38	M	Yes/Aj	3	CA	No	Single	Triple	23	24
3	32	M	Yes	4	CA	No	Single	Noninducible	5	20
4	24	M	Yes	4	CA	No	Double	Triple	36	20
5	52	M	Yes/Aj	6	CA	No	Double	Noninducible	83	20
6	45	M	Yes	2	CA	No	Double	Noninducible	7	17
7	35	M	Yes	5	CA	No	Double	Noninducible	12	20
8	53	M	Yes	2	CA	No	Triple	Noninducible	60	12
9	47	M	Yes	6	CA	No	Double	Noninducible	16	12
Median	38			4					16	20

Aj indicates ajmaline; BrS, Brugada syndrome; ICD, implantable cardioverter-defibrillator; CA, cardiac arrest; and VF, ventricular fibrillation.

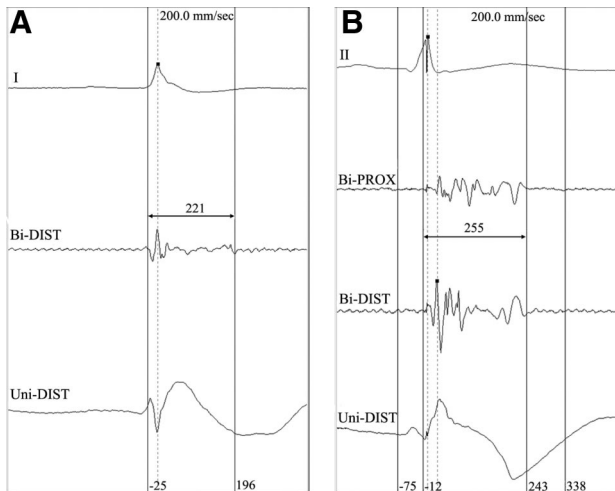


Figure 2. Examples of electrograms with fractionated LPs that present as good target sites for catheter ablation. **A** exhibits a low-voltage electrogram (0.33 mV) with long fractionated potential of 221 ms that coincides with the appearance of the unipolar J-point elevation identical to the typical Brugada ECG pattern. **B** shows multiple fractionated late potentials (LPs) recorded from both proximal (Bi-PROX) and distal (Bi-DIST) pairs of the NaviStar electrodes located at the anterior right ventricular outflow tract (RVOT) epicardium. All 3 electrograms have typical patterns and late activations recorded from the ideal sites for catheter ablation of ventricular tachycardia/ventricular fibrillation (VT/VF) substrates of the Brugada syndrome (BrS) patients in this study. Uni-DIST indicates unipolar distal.

over the month preceding the study. All patients had a positive type 1 Brugada ECG pattern, spontaneously occurring in 7 and after ajmaline infusion in 2 patients. None of the patients had structural heart disease, as evidenced by normal cardiac catheterization, cardiac CT/magnetic resonance imaging, and 2-dimensional echocardiogram. Programmed electric stimulation revealed inducible VT/VF in all patients (Table 1).

Table 2 summarizes mapping details and pertinent procedural data of each patient. The median procedure, fluoroscopic, and cumulative radiofrequency times are 180, 15.4, and 25 minutes, respectively.

Fractionation and Conduction Delay Over the Anterior Wall of RVOT Epicardium

All 9 patients had normal electrograms derived from the RVOT endocardium. To the contrary, we observed a confluence

of abnormal epicardial electrograms characterized by fragmented electrograms exhibiting relatively low voltage (<1 mV), prolonged duration, and late polyphasic potentials exclusively localized over the anterior aspect of the RVOT epicardium.

Figure 3 shows an example of such abnormal ventricular electrograms recorded in the area of the anterior RVOT epicardium of patient 4. The double annotation map (A2-A1) shows that patient 4 had abnormal prolonged ventricular electrograms (>150 ms), as displayed in purple in this area. These electrograms also were fractionated and low voltage (<1 mV), as displayed in red in the bipolar-voltage map. Note that the sample of the electrograms recorded from this area of the RVOT epicardium display markedly delayed depolarization, as shown by the LP that continued to depolarize beyond the QRS complex (160 ms), with the width of the electrogram of 183 ms and a very low voltage of 0.84 mV.

These abnormal electrograms were not found at the endocardial site of the same area of the RVOT, as shown in Figure 4. Note that the endocardial site (arrow) in this Figure displays a single potential of 2.09 mV, with a duration of 58 ms, and did not extend beyond the QRS complex compared to the epicardial counterpart that showed low-voltage LP (0.48 mV), with a duration of 236 ms.

As shown in Table 3 (distribution and characteristics of electrograms of each individual patient are available in the online-only Data Supplement Table 1), the voltage of these fractionated electrograms in the anterior epicardial RVOT region was 0.94 ± 0.79 mV compared to the other 3 mapping areas (the rest of the RV epicardium, LV epicardium, and RV endocardium; $P < 0.001$).

Figure 5 shows epicardial electrograms recorded from various sites of the epicardium in both the LV and RV epicardium. Note that abnormal fractionated electrograms and double potential electrograms are only localized in the anterior aspect of the RVOT epicardium.

The distribution of abnormal fractionated electrograms—low-voltage signals (<1 mV), LP extended >100 ms from the end of QRS complex, and wide duration (>80 ms)—is almost exclusively located at the anterior RVOT epicardium. Figure 6 clearly shows that almost all abnormal electrograms that are deemed appropriate for ablation targets, as described above, are those recorded from the anterior RVOT epicardium. Table 3 summarizes characteristics of ventricular electrograms of each patient in the 4 main mapping areas. Note that epicardial electrograms from the anterior RVOT were also prolonged in duration and had a delayed onset of activation, which occurred very late after the QRS complex. The duration of these abnormal epicardial electrograms was 132 ± 47 ms, which was much longer than the other 3 sites: RV epicardium (75 ± 28 ms), LV epicardium (60 ± 17 ms), and RV endocardium (66 ± 21 ms) ($P < 0.001$). The interval from the end of the QRS complex to the end of the electrograms was 96 ± 47 ms, which was much later in the anterior RVOT epicardial site compared to RV epicardium (32 ± 31 ms), LV epicardium (6 ± 19 ms), and the RV endocardium (13 ± 23 ms) ($P < 0.001$).

Importantly, unipolar electrograms recorded from this area with delayed fragmented potentials showed a remarkably

Table 2. Relevant Procedural Details of the Study Patients

Patient	Procedure Time, min	Fluoroscopic Time, min	Ablation Points, n	Ablation Time, min
1	145	15.4	15	7.4
2	188	16.3	35	21
3	203	18.3	40	31
4	196	14.3	46	24.8
5	153	11.5	29	20.3
6	176	14	49	31.9
7	159	14.8	14	6.4
8	180	20.1	32	26
9	197	19	35	25.2
Median	180	15.4	35	24.8

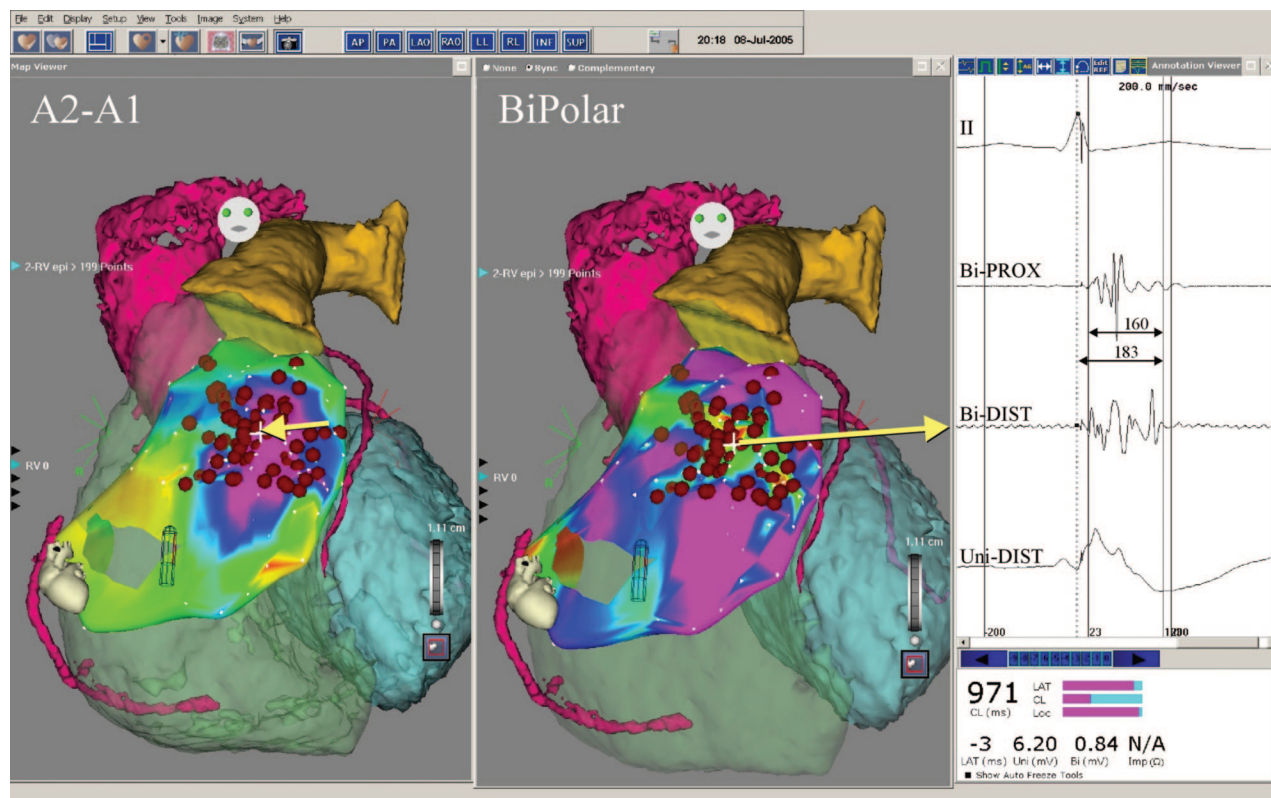


Figure 3. A composite picture of the CARTO-merge maps (patient 4) shows the cardiac computed tomography that is merged with the electroanatomic maps of the right ventricular outflow tract (RVOT) epicardium (epi). The double annotation map (A2-A1), shown on the left, illustrates the scale of abnormal prolonged duration of the ventricular electrograms in the anterior RVOT as displayed in the color-coded area; the purple represents the longest duration (>160 ms) during sinus rhythm. The voltage map, shown in the middle, is the same as the A2-A1 map but is displayed differently, with the color-coded area of low voltage in red and high voltage in purple. The right inset displays the electrograms recorded from the NaviStar-ThermoCool catheter at the site of the anterior aspect of the RVOT epicardium (arrow; refer to the text for details). Red dots represent ablation points. The voltage map and the representative tracing of the bipolar and unipolar electrograms are recorded from the anterior aspect of the RVOT epicardium. Note that the duration of the electrograms in this area is quite prolonged (>150 ms) and low voltage (<1 mV). The bipolar electrogram recorded from this site shows the electrogram is low voltage (0.84 mV), fractionated, and has prolonged duration (183 ms) and delayed depolarization beyond the end of the lead II-QRS complex (160 ms). Bi-DIST indicates bipolar distal; Bi-PROX, bipolar proximal; Uni-DIST, unipolar distal; LAT, local activation time; CL, cycle length; Loc, location; Uni, unipolar; Bi, bipolar; and Imp, impedance.

identical Brugada pattern, as seen in the right precordial leads. As shown in Figures 1 through 3, the unipolar electrograms appeared as ST elevation because of delayed depolarization after the QRS complex in this small area of the anterior RVOT epicardium, manifested as the prolonged unipolar electrograms that were identical to the signature ST elevation of the Brugada ECG pattern.

Ablations of the Epicardial Substrate Suppressing VT/VF Induction

Catheter ablations were performed during sinus rhythm over these abnormal areas at the epicardial sites of the anterior aspect of the RVOT. All 9 patients had inducible VT/VF at baseline before ablation, which had become noninducible in 7 of 9 patients (78%) after the ablation (95% confidence interval, 0.40 to 0.97; $P=0.015$); in the other 2 patients, VT became very difficult to induce, changing from a single extra stimulus in one patient (patient 2) and double stimuli in the other (patient 4) to triple ventricular stimuli after the ablation (Table 1). However, both patients displayed normalization of the Brugada ECG pattern, as described below. Patient 2 had ajmaline provocation at the time of

the initial diagnosis, but his ECG pattern occurred spontaneously on the day of the procedure and became normalized after the procedure.

Effects of the Epicardial Ablation on the Brugada ECG Pattern

Epicardial ablation resulted in normalization of the Brugada ECG pattern during the procedure in 5 of the 9 patients. Figure 7 demonstrates the effect of the ablation on the ECG pattern in patient 4; the patient had a typical type 1 Brugada ECG pattern in V1 and V2, which normalized at the end of the ablation procedure. Interestingly, of the 4 patients whose Brugada ECG pattern remained immediately after the ablation, 3 had their Brugada ECG pattern normalize within 3 months (Figure 8), resulting in 8 out of 9 patients (89%) in the study having a normal ECG pattern after the ablation (95% confidence interval, 0.52 to 0.99; $P=0.008$).

Long-Term Clinical Outcomes

At a mean follow-up of 20 ± 6 months, only 1 of 9 patients (patient 1 is the exception) had any recurrences of VF episodes, and there were no shocks from the ICD for patients

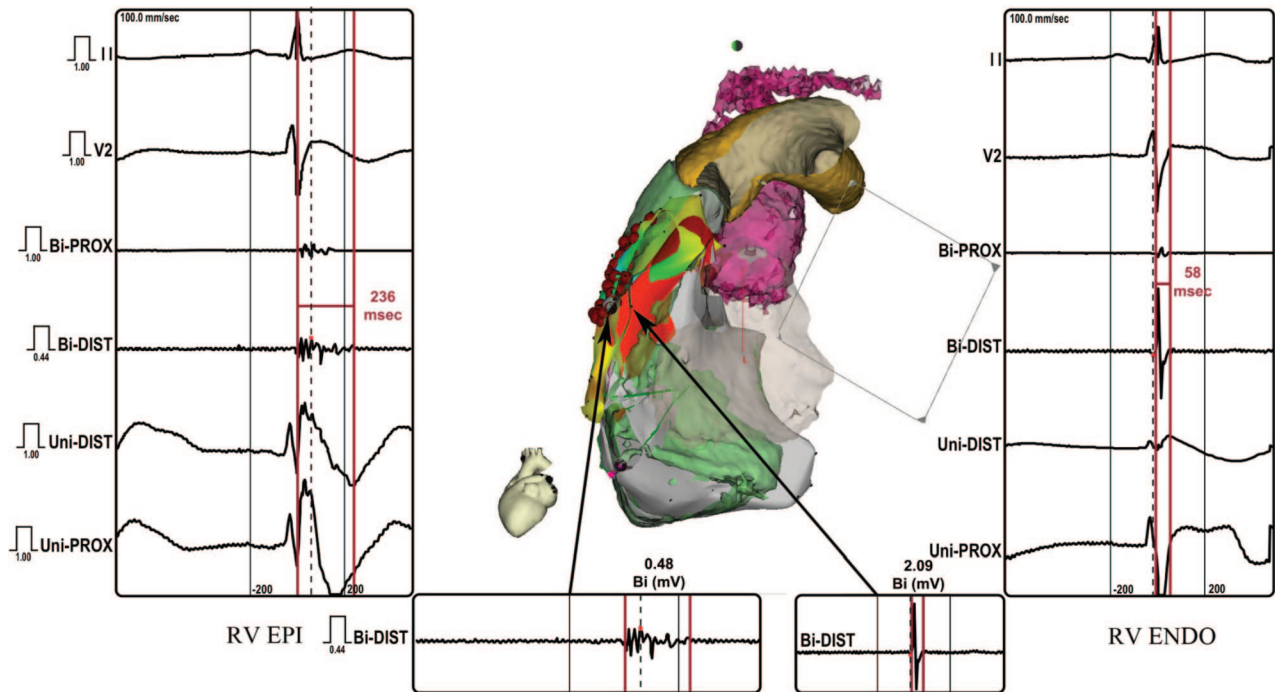


Figure 4. Left lateral view of the right ventricular outflow tract (RVOT) displays the difference in ventricular electrograms between the endocardial (ENDO) and epicardial (EPI) site of the anterior RVOT of the same patient (patient 4) as Figure 2. The left and right insets display bipolar and unipolar electrograms recorded from the epicardium and endocardium from the same site of the RVOT, respectively. Bi-DIST indicates bipolar distal; Bi-PROX, bipolar proximal; Uni-DIST, unipolar distal; and Uni-PROX, unipolar proximal.

off antiarrhythmic drugs (signed-rank test VF: $P=0.004$). Patient 1, who had an average of 4 episodes per month on amiodarone compared to 15 episodes per month prior to amiodarone treatment, had only 1 VF recurrence after the ablation and after stopping the drug. After amiodarone was resumed at 100 mg daily, there were no VT/VF recurrences up to 33 months after the ablation.

Complications

There were no complications after the ablation except mild pericarditis in 2 patients; this was quickly resolved within 1 week.

Discussion

This study reveals several new important findings about the BrS relative to both therapeutic options and its pathophysio-

logical mechanism. First, our observation unequivocally demonstrates that patients with BrS have abnormal delayed depolarization over the anterior aspect of the RVOT epicardium. Second, our study suggests that the anterior RVOT epicardium is likely to be the arrhythmogenic area underlying the BrS. Third, catheter ablation over this abnormal anterior epicardium of the RVOT results in normalization of the Brugada ECG pattern. Fourth, our study is the first to show that catheter ablation over this area may lead to prevention of recurrent VT/VF in BrS patients with frequent recurrent VF episodes.

Delayed Depolarization as Underlying Electrophysiological Mechanism

The abnormal depolarization over the RVOT epicardium observed in this study is characterized by abnormal low-voltage fractionated ventricular electrograms (<1 mV) that have a markedly delayed conduction time after QRS complex on the surface ECG (>100 ms) and a markedly prolonged duration (>130 ms). These abnormal electrograms are exclusively localized in a cluster over the epicardium of the anterior aspect of the RVOT and are not seen anywhere else in either ventricle.

The endocardial site at the same region of the anterior RVOT does not exhibit the same magnitude of these abnormalities. Postema et al reported on their RV endocardial mapping study, which showed that type 1 BrS patients had delayed activation time at the RVOT area associated with prolonged fractionated electrograms.¹³ Their findings, like ours, suggest that delayed depolarization over the RVOT area contributes to the Brugada ECG pattern. However, the magnitude of our electrogram abnormalities over the RVOT

Table 3. Characteristics of Electrograms Among 4 Mapping Areas

Electrogram Characteristics	RV Epicardium (n=261)	Anterior RVOT Epicardium (n=189)	LV Epicardium (n=164)	RV Endocardium (n=213)
Bipolar, mV*	1.35±1.2	0.94±0.79	2.81±2	3±2.7
LP, ms*	32±31	96±47	6±19	13±23
Electrogram duration, ms*	76±28	132±48	60±17	66±21

Data presented as mean±SD.

*ANOVA test: $P<0.001$.

RV indicates right ventricle; RVOT, right ventricular outflow tract; LV, left ventricle; and LP, late potential.

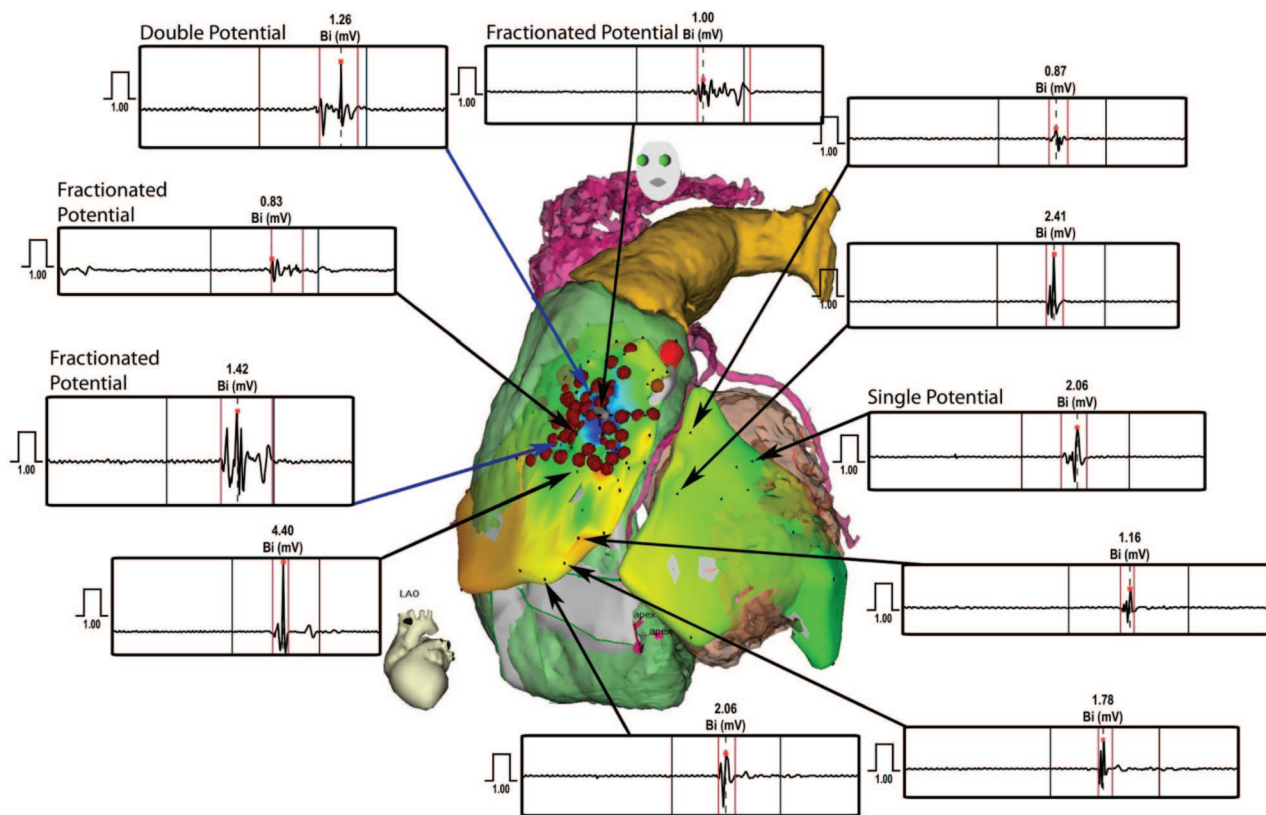


Figure 5. Comparison of ventricular electrograms recorded from different sites in both the left ventricle (LV) and right ventricle (RV) of the same patient as Figures 3 and 4 (patient 4).

epicardium is much greater than those observed in the RV endocardium in the Postema study.

Fractionated electrograms are a common manifestation of increased coupling resistance following separation of myocardial fibers by fibrosis or fat.^{14,15} They may also result from functional derangements (eg, functional block and current-to-load mismatch).^{16–18} In any case, this illustrates that the

electric impulse travels discontinuously in this area, and provides strong evidence that the anterior RVOT epicardium is the arrhythmogenic substrate in these patients with BrS.

In addition, the unipolar recording of the electrograms in this area shows that the cove-type pattern is identical to that of the signature Brugada ECG pattern in the right precordial leads (Figures 1 through 3). Hence, there seems to be little

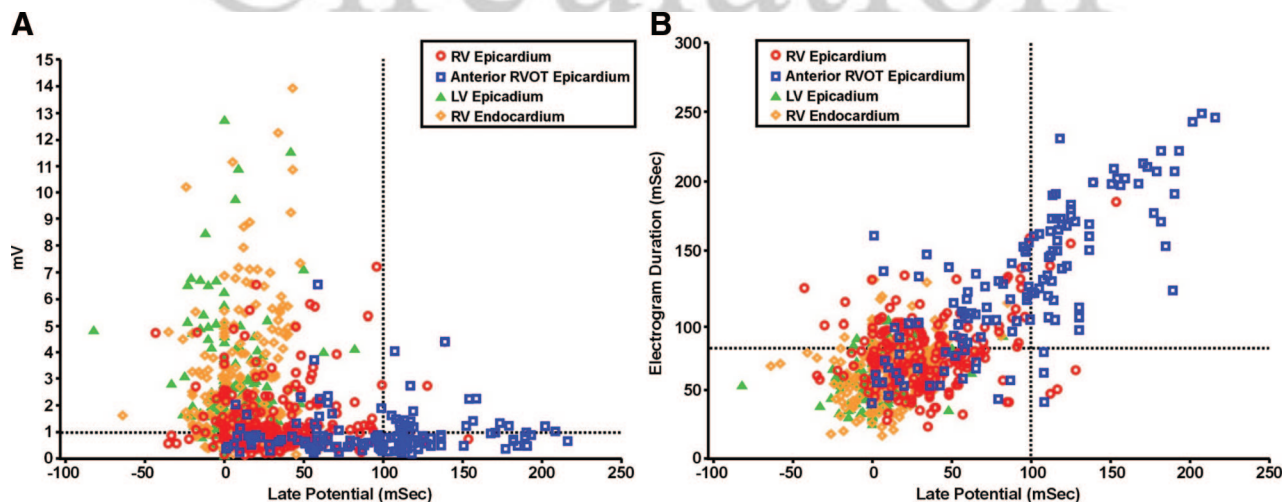


Figure 6. A scattered plot of all electrograms ($n=827$ points) recorded from the 9 patients from the 4 major areas: right ventricular (RV) epicardium, anterior right ventricular outflow tract (RVOT) epicardium, left ventricular (LV) epicardium, and RV endocardium. **A**, scattered plots of late potential (LP) versus electrogram bipolar voltage (BimV) clearly demonstrate that low-voltage signals (<1 mV) with LP (>100 ms of the end of QRS complex) are exclusively from those recorded from anterior RVOT epicardium. **B**, Scattered plots of LP versus electrogram duration show similarly that the quadrant of LPs >100 ms and electrogram width >100 ms are almost entirely housed by the signals recorded from the anterior RVOT epicardium.

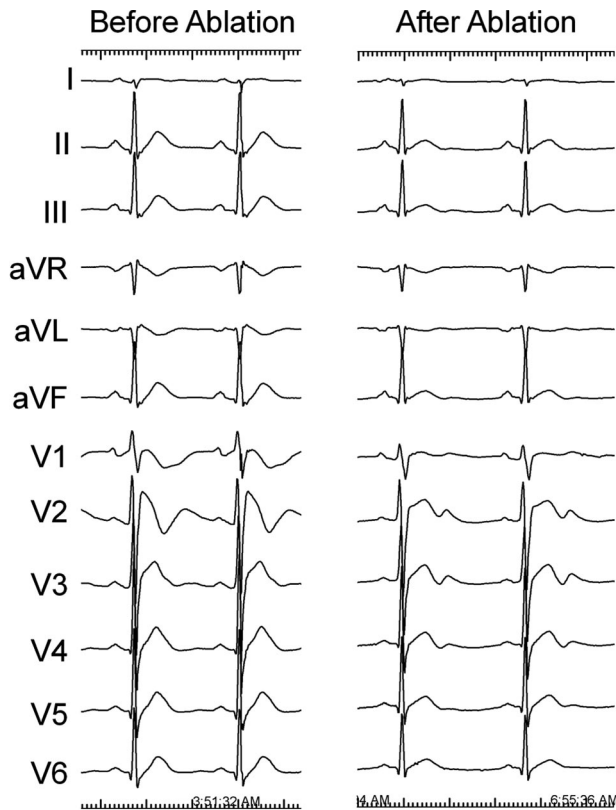


Figure 7. The 12-lead ECGs from the same patient (patient 4), recorded at the beginning and end of the procedure, show normalization of the Brugada ECG pattern during the ablation.

doubt that the unipolar recording at the anterior aspect of the RVOT epicardium shows this Brugada pattern because of the delayed depolarization process over this area; therefore, these findings unequivocally support the depolarization disorder hypothesis (ie, conduction delay or conduction failure in the RVOT, in particular, causing local ST elevation as the electrophysiological mechanism underlying the BrS).^{19,20} The

repolarization hypothesis (ie, a transmural gradient in repolarization pattern through the RV wall)²¹ does not find much support in these findings, but some contribution of repolarization gradients to the characteristic ECG pattern cannot be excluded.

Effects of Catheter Ablation

The follow-up data lend further support for the preceding conclusions. Indeed, ablation at the epicardial sites that exhibit this abnormal delayed depolarization resulted in normalization of the ECG pattern in 8 out of 9 patients. The only patient who continues to have an abnormal Brugada ECG pattern subsequently had a few radiofrequency applications at the RVOT epicardium, resulting in noninducible VT/VF after the ablation. Although it is unclear whether more applications over these areas would have normalized the ECG, we speculate that more applications to the wider area of the anterior RVOT epicardium in this patient, similar to those performed on the other 8 patients, will likely cause the Brugada ECG pattern to disappear. In any event, the normalization of the ECG pattern after the catheter ablation over the anterior epicardium of the RVOT in the other 8 patients clearly suggests that this is the primary site for arrhythmogenic substrate in patients with BrS, and conduction disturbances underlie the right precordial ST elevation.

There was a significant suppression of inducible polymorphic VT/VF after catheter ablation of this arrhythmogenic area, which provides further proof that the epicardium of the anterior RVOT is the arrhythmogenic site in these BrS patients. Seven of the 9 patients (78%) had no inducible sustained ventricular arrhythmias after the ablation whereas all of them had inducible VT/VF at baseline. More importantly, spontaneous VF episodes causing multiple ICD discharges completely dissipated after the ablation. During a mean of almost 2 years of follow-up, there were no recurrent VT/VF episodes requiring ICD discharges in any of the study patients.

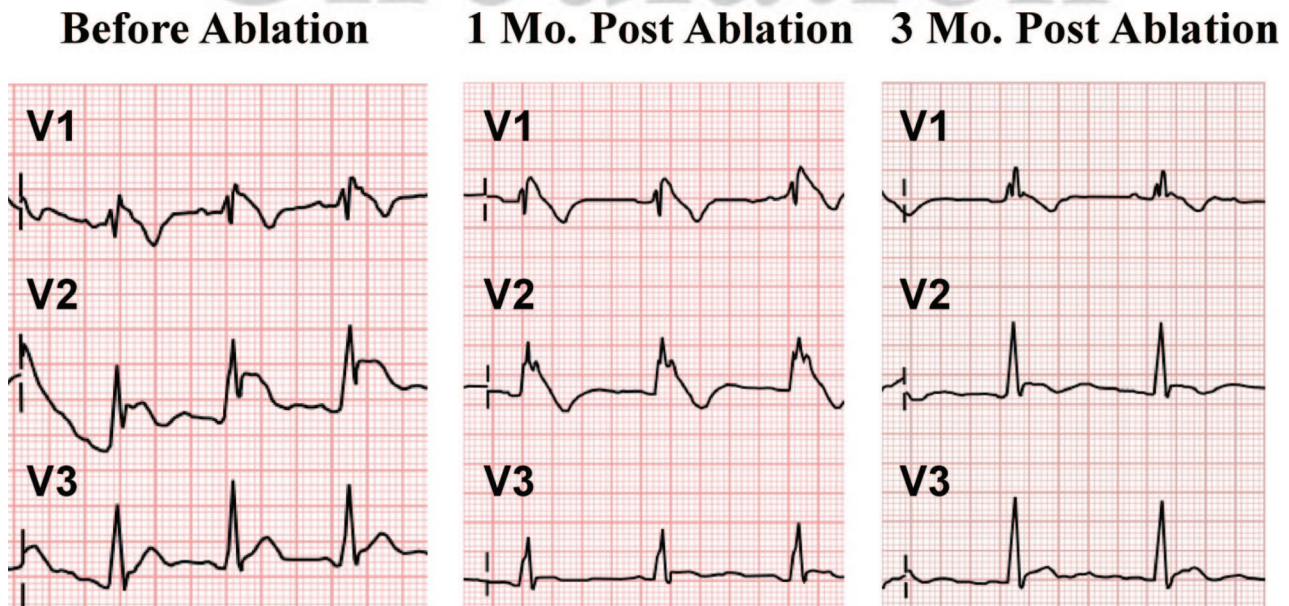


Figure 8. A delayed effect of epicardial ablation on the ECG pattern. The ECG pattern of patient 7 took 3 months to normalize.

Thus, catheter ablation offers an alternative therapeutic modality for patients with BrS/sudden unexplained death syndrome, especially when ICD storms are encountered. Our finding that ablation is effective in preventing Vt/VF is the same as previous reports by Haïssaguerre et al.⁷ However, our approach is different because we are the first to ablate substrate at the RVOT epicardium whereas previous investigators merely targeted PVCs at the endocardial site of the RVOT, which triggered VF episodes.

Moreover, BrS patients rarely have frequent PVCs to be mapped, making this approach impractical, as evidenced by the fact that an insignificant number of patients are being treated by this ablative approach. None of our 9 patients had PVCs to be mapped during the study. However, all 9 patients from our study had the arrhythmogenic substrate at the same location: the anterior epicardium of the RVOT. It is therefore highly likely that the arrhythmogenic substrate in patients with BrS is at this site. This finding will give electrophysiologists a specific location of where to look for areas that harbor abnormal low-voltage fractionated LP to ablate.

Our finding that the anterior aspect of RVOT epicardium is the arrhythmogenic substrate causing depolarization disorder in patients with BrS will inevitably raise the question, do patients with BrS have the same disease process as patients with arrhythmogenic right ventricular cardiomyopathy? Although the characteristics of ventricular electrograms at the RVOT epicardium in our patients are similar to those described by Garcia et al²² in patients with arrhythmogenic right ventricular cardiomyopathy, none of our patients had any evidence of arrhythmogenic right ventricular cardiomyopathy by magnetic resonance imaging (before ICD implantation), RV angiogram, echocardiography, or repeat cardiac CT.

Study Limitations

Our study included only 9 patients, which may be considered a small sample size. However, we decided to first study patients with frequent ICD discharges who failed to respond to antiarrhythmic agents and were in dire need of effective treatment to prevent recurrent VF episodes. Our ablation treatment and our findings are uniformly consistent in all patients, enabling us to draw firm conclusions. We did not perform a genetic study in these patients; however, it is unlikely that the genetic findings would affect our results and findings.

In addition, one may question the validity of the normalization of the Brugada ECG pattern because it is well known that the ECG pattern in some patients with BrS is wax and wane. However, 7 of the 9 patients had their Brugada ECG pattern persistently over many years without changes and therefore it is very unlikely that our findings are due to the spontaneous disappearance of the ECG pattern. Furthermore, during the follow-up period, the Brugada ECG pattern reappeared in only 1 of the 9 patients.

Clinical Implications

This study provides major findings that have therapeutic value: We now can find the arrhythmogenic substrate that serves very well as target sites for catheter ablation and thus can expect a good clinical outcome. Whether ablation would substitute for an

ICD in high-risk BrS patients remains unknown. Further studies clearly need to be done to assess values and limitations of catheter ablation in patients with BrS.

Sources of Funding

This study was supported by CAPRE and Vejdisut Foundation of Thailand and Grants-in Aid from Adventis Health Organization at White Memorial Hospital and Biosense-Cordis Webster Inc.

Disclosures

Dr Nademanee has consulting agreements with Biosense Webster Inc., receives research grants from Biosense Webster Inc. and Medtronic Inc., and receives royalties from Biosense Webster Inc. The other authors report no conflicts.

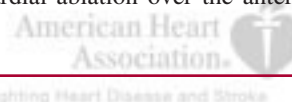
References

- Brugada P, Brugada J. Right bundle branch block, persistent ST segment elevation and sudden cardiac death: a distinct clinical and electrocardiographic syndrome: a multicenter report. *J Am Coll Cardiol*. 1992;20:1391–1396.
- Nademanee K, Veerakul G, Nimmannit S, Chaowakul V, Bhuripanyo K, Likittanasombat K, Tunsanga K, Kuasirikul S, Malasit P, Tansupasawadikul S, Tatsanavivat P. Arrhythmogenic marker for the sudden unexplained death syndrome in Thai men. *Circulation*. 1997;96:2595–2600.
- Vatta M, Dumaine R, Varghese G, Richard TA, Shimizu W, Aihara N, Nademanee K, Brugada R, Brugada J, Veerakul G, Li H, Bowles N, Brugada P, Antzelevitch A, Towbin JA. Genetic and biophysical basis of sudden unexplained nocturnal death syndrome (SUNDS), a disease allelic to Brugada syndrome. *Hum Mol Genet*. 2002;11:337–345.
- Nademanee K, Veerakul G, Mower M, Likittanasombat K, Krittayapong R, Bhuripanyo K, Sitthisook S, Chaohawee L, Lai MY, Azen SP. Defibrillator Versus beta-Blockers for Unexplained Death in Thailand (DEBUT): a randomized clinical trial. *Circulation*. 2003;107:2221–2226.
- Belhassen B, Glick A, Viskin S. Efficacy of quinidine in high-risk patients with Brugada syndrome. *Circulation*. 2004;110:1731–1737.
- Nagase S, Kusano KF, Morita H, Fujimoto Y, Kakishita M, Nakamura K, Emori T, Matsubara H, Ohe T. Epicardial electrogram of the right ventricular outflow tract in patients with the Brugada syndrome: using the epicardial lead. *J Am Coll Cardiol*. 2002;39:1992–1995.
- Haïssaguerre M, Extramiana F, Hocini M, Cauchemez B, Jais P, Cabrera J, Farre G, Leenhardt A, Sanders P, Scavee C, Hsu LF, Weerasooriya R, Shah D, Frank R, Maury P, Garrigue S, Clementy J. Mapping and ablation of ventricular fibrillation associated with long-QT and Brugada syndromes. *Circulation*. 2003;108:925–928.
- Tuikie R, Sogaard P, Vleugels J, de Groot IK, Wilde AA, Tan HL. Delay in right ventricular activation contributes to Brugada syndrome. *Circulation*. 2004;109:1272–7.
- Antzelevitch C, Brugada P, Borggreffe M, Brugada J, Brugada R, Corrado D, Gussak I, LeMarec H, Nademanee K, Perez Riera AR, Shimizu W, Schulze-Bahr E, Tan H, Wilde A. Brugada syndrome: report of the second consensus conference. *Heart Rhythm*. 2005;2:429–440.
- Krittayapong R, Veerakul G, Nademanee K, Kangkagate C. Heart rate variability in patients with Brugada syndrome in Thailand. *Eur Heart J*. 2003;24:1771–1778.
- Wilde AA, Antzelevitch C, Borggreffe M, Brugada J, Brugada R, Brugada P, Corrado D, Hauer R, Kass R, Nademanee K, Priori S, Towbin J. Proposed diagnostic criteria for the Brugada syndrome: consensus report. *Circulation*. 2002;106:2514–2519.
- Sosa E, Scanavacca M, d'Avila A, Pilleggi F. A new technique to perform epicardial mapping in the electrophysiology laboratory. *J Cardiovasc Electrophysiol*. 1996;7:531–536.
- Postema PG, van Dessel PF, de Bakker JM, Dekker LR, Linnenbank AC, Hoogendijk MG, Coronel R, Tijssen JG, Wilde AA, Tan HL. Slow and discontinuous conduction conspire in Brugada syndrome: a right ventricular mapping and stimulation study. *Circ Arrhythmia Electrophysiol*. 2008;1:379–386.
- de Bakker JM, van Capelle FJ, Janse MJ, Tasseron S, Vermeulen JT, de Jonge N, Lahpor JR. Slow conduction in the infarcted human heart: “zigzag” course of activation. *Circulation*. 1993;88:915–926.

15. Corrado D, Basso C, Leoni L, Tokajuk B, Bauce B, Frigo G, Tarantini G, Napodano M, Turrini P, Ramondo A, Daliento L, Nava A, Buja G, Illiceto S, Thiene G. Three-dimensional electroanatomic voltage mapping increases accuracy of diagnosing arrhythmogenic right ventricular cardiomyopathy/dysplasia. *Circulation*. 2005;111:3042–3050.
16. Saumarez RC, Chojnowska L, Derksen R, Pytkowski M, Sterlinski M, Huang CL, Sadoul N, Hauer RN, Ruzyllo W, Grace AA. Sudden death in noncoronary heart disease is associated with delayed paced ventricular activation. *Circulation*. 2003;107:2595–2600.
17. Turner I, Huang H, Saumarez RC. Numerical simulation of paced electrogram fractionation: relating clinical observations to changes in fibrosis and action potential duration. *J Cardiovasc Electrophysiol*. 2005;16:151–161.
18. Kucera JP, Kleber AG, Rohr S. Slow conduction in cardiac tissue, II: effects of branching tissue geometry. *Circ Res*. 1998;83:795–805.
19. Meregalli PG, Wilde AA, Tan HL. Pathophysiological mechanisms of Brugada syndrome: depolarization disorder, repolarization disorder, or more? *Cardiovasc Res*. 2005;67:367–378.
20. Postema PG, van Dessel PF, Kors JA, Linnenbank AC, van Herpen G, Ritsema van Eck HJ, van Geloven N, de Bakker JM, Wilde AA, Tan HL. Local depolarization abnormalities are the dominant pathophysiologic mechanism for type 1 electrocardiogram in Brugada syndrome: a study of electrocardiograms, vectorcardiograms, and body surface potential maps during ajmaline provocation. *J Am Coll Cardiol*. 2010;55:789–797.
21. Antzelevitch C, Brugada P, Brugada J, Brugada R, Towbin JA, Nademanee K. Brugada syndrome: 1992–2002: a historical perspective. *J Am Coll Cardiol*. 2003;41:1665–1671.
22. Garcia F, Bazan V, Zado E, Ren JF, Marchlinski FE. Epicardial substrate and outcome with epicardial ablation of ventricular tachycardia in arrhythmogenic right ventricular cardiomyopathy/dysplasia. *Circulation*. 2009;120:366–375.

CLINICAL PERSPECTIVE

Several studies have indicated that the right ventricular outflow tract (RVOT) is likely to be the electrophysiological substrate site in patients with Brugada syndrome (BrS). However, controversy exists as to whether the underlying electrophysiological mechanism that causes an abnormal ECG pattern and ventricular tachycardia/ventricular fibrillation (VT/VF) in BrS patients is due to a repolarization or depolarization abnormality. We performed electroanatomical mapping of the right ventricular (RV) endocardium and both ventricular epicardium in 9 patients with symptomatic BrS who had frequent implantable cardioverter defibrillator discharges due to VT/VF. All 9 patients were found to have abnormal low voltage (<1 mV) and fractionated late potentials present almost exclusively over the anterior aspect of the RVOT epicardium and not elsewhere. These abnormal electrograms are also characterized by markedly prolonged duration of the signals that represent delayed depolarization coinciding with timing of the J-point ST elevation of the typical type 1 Brugada ECG pattern. Furthermore, ablation at the anterior RVOT epicardium resulted in normalizing Brugada ECG pattern in 8 of the 9 patients (89%) and prevented VT/VF induction in 7 of the 9 patients (78%). All patients except 1 were free of VT/VF episodes after at least 1 year of follow-up. These findings suggest that the anterior RVOT epicardium is the arrhythmogenic substrate site in BrS patients, and abnormal delayed depolarization is likely the main electrophysiological mechanism underlying the BrS. This study is also the first to show that epicardial ablation over the anterior RVOT is effective in preventing recurrent VT/VF.



Circulation
JOURNAL OF THE AMERICAN HEART ASSOCIATION

SUPPLEMENTAL MATERIAL

Supplemental Table 1. Characteristics of Ventricular Electrograms of Study Patients.

		Bipolar (mV) *				Late Potential (msec)*				Electrogram Duration (msec)*			
		RV-EPI	ANT RVOT EPI	LV EPI	RV ENDO	RV-EPI	ANT RVOT EPI	LV EPI	RV ENDO	RV-EPI	ANT RVOT EPI	LV EPI	RV ENDO
Patient	n												
1	62	0.75 ± 0.33	0.44 ± 0.1	2.55 ± 1.31	3.49 ± 2.56	27 ± 22	93 ± 31	13 ± 26	20 ± 19	73 ± 17	120 ± 18	57 ± 47	77 ± 13
		(n=26)	(n=6)	(n=15)	(n=15)	(n=26)	(n=6)	(n=15)	(n=15)	(n=26)	(n=6)	(n=15)	(n=15)
2	71	1.11 ± 1.05	0.49 ± 0.25	1.99 ± 0.52	3.07 ± 2.57	15.29 ± 20	68.17 ± 14	5 ± 12	-3.59 ± 16	62.25 ± 16	82.93 ± 15	46 ± 8	47.82 ± 13
		(n=20)	(n=15)	(n=14)	(n=22)	(n=20)	(n=15)	(n=14)	(n=22)	(n=20)	(n=15)	(n=14)	(n=22)
3	43	0.73 ± 0.23	0.5 ± 0.13	0.86 ± 0.26	2.74 ± 1.95	22.92 ± 16.35	86.4 ± 30	25 ± 7	3.78 ± 12	56.69 ± 14.56	107.6 ± 28	49 ± 1.41	33.61 ± 9
		(n=13)	(n=10)	(n=2)	(n=18)	(n=13)	(n=10)	(n=2)	(n=18)	(n=13)	(n=10)	(n=2)	(n=18)
4	170	1.53 ± 1	1.1 ± 0.68	3.87 ± 3.15	2.83 ± 3	55.58 ± 33	127.07 ± 43	18.85 ± 22	10.17 ± 15	73.85 ± 32	160.3 ± 43	63.86 ± 16	61.39 ± 13.53
		(n=64)	(n=60)	(n=28)	(n=18)	(n=64)	(n=60)	(n=28)	(n=18)	(n=64)	(n=60)	(n=28)	(n=18)
5	106	2.17 ± 1.41	1.55 ± 0.96	1.77 ± 3.67 ± 2	0.81	20.97 ± 27.50	68.15 ± 45	9.38 ± 22	9.93 ± 21	81.59 ± 21	116.95 ± 42	74.92 ± 13.51	75.07 ± 22
		(n=58)	(n=20)	(n=13)	(n=15)	(n=58)	(n=20)	(n=13)	(n=15)	(n=58)	(n=20)	(n=13)	(n=15)
6	112	1.06 ± 1.25	1.07 ± 1.04	1.83 ± 1.11	2.63 ± 2.81	17.28 ± 26	90.08 ± 49	2.27 ± 20	12.93 ± 32	81.55 ± 15.44	132.83 ± 46	44.4 ± 15	80.46 ± 19
		(n=23)	(n=46)	(n=15)	(n=28)	(n=23)	(n=46)	(n=15)	(n=28)	(n=23)	(n=46)	(n=15)	(n=28)
7	102	0.76 ± 0.67	0.64 ± 0.32	3.08 ± 0.99	3 ± 2.71	31.41 ± 28	112.92 ± 16	8 ± 10	17.37 ± 24	68.35 ± 35	87.33 ± 31	80.45 ± 15	67 ± 19
		(n=20)	(n=9)	(n=11)	(n=62)	(n=20)	(n=9)	(n=11)	(n=62)	(n=20)	(n=9)	(n=11)	(n=62)
8	93	1.1 ± 1.39	0.58 ± 0.15	2.44 ± 1.52	3.44 ± 2.58	36.99 ± 32	63.81 ± 31	-1.74 ± 16	19.94 ± 18	83.24 ± 24	119.64 ± 35	56.24 ± 14	77.31 ± 12
		(n=25)	(n=14)	(n=38)	(n=16)	(n=25)	(n=14)	(n=38)	(n=16)	(n=25)	(n=14)	(n=38)	(n=16)
9	68	0.84 ± 0.53	0.37 ± 0.20	2.98 ± 2.50	4.66 ± 3.36	34.42 ± 36	62.23 ± 49	1.36 ± 16	25.95 ± 14	93.83 ± 58	161.22 ± 64	61.32 ± 13	68.68 ± 18
Mean ± SD		1.35 ± 1.2	0.94 ± 0.79	2.8 ± 2	3 ± 2.7	32 ± 31	96 ± 47	6 ± 19	13 ± 23	76 ± 28	132 ± 48	60 ± 17	66 ± 21

RV-EPI = right ventricular epicardium; ANT RVOT EPI = anterior right ventricular outflow tract epicardium; LV EPI = left ventricular epicardium; RV ENDO = right ventricular endocardium.